

Evaluation of the Apical Sealability of Mineral Trioxide Aggregate and Portland Cement as Root Canal Filling Cements: An in Vitro Study

M.S. Rekab¹, H. Rushdi Ayoubi²✉

¹Professor, Department of Endodontics, School of Dentistry, Damascus University of Medical Sciences, Damascus, Syria

²PhD Student, Department of Endodontics, School of Dentistry, Damascus University of Medical Sciences, Damascus, Syria

Abstract:

Objective: One of the principle purposes of root canal obturation is to obtain hermetic sealing of the root canal system. According to the development of technology, many materials are now used in root canal filling. An in vitro dye leakage study was performed to evaluate the apical sealability of White-colored Mineral Trioxide Aggregate (WMTA) and Gray-colored Portland Cement (GPC) when used alone or as a sealer with gutta-percha points in root canal filling.

Materials and Methods: Seventy-five single-rooted extracted human teeth were used in this study. After cleaning and shaping, the teeth were randomly divided into five equal groups of 15 teeth each based on the root canal filling material used; Group 1, (WMTA) alone; Group 2, (GPC) alone; Group 3, (Gutta-percha points + WMTA); Group 4, (Gutta-percha points + GPC); Group 5, (Gutta-percha points + AH26). Methylene blue was used to determine the apical leakage. After sectioning the teeth longitudinally, linear dye penetration was measured with a caliper under the stereomicroscope. Data were analyzed by Kruskal-Wallis and one-way ANOVA tests with ($P \leq 0.05$) as the level of significance.

Results: The results showed that there were no statistically significant differences among the materials of five groups.

Conclusion: (WMTA) alone, (Gutta-percha points + WMTA), (GPC) alone and (Gutta-percha points + GPC) may be used in the root canal filling.

Key Words: Apical Sealability; Mineral Trioxide Aggregate (MTA); Portland Cement (PC); Root Canal Filling

Journal of Dentistry, Tehran University of Medical Sciences, Tehran, Iran (2010; Vol.7, No.4)

✉ Corresponding author:
H. Ayoubi, PhD Student, Department of Endodontics, School of Dentistry, Damascus University of Medical Sciences, Damascus, Syria
dr.helen_ayoubi@yahoo.com

Received: 30 March 2010

Accepted: 28 June 2010

INTRODUCTION

Microorganisms play an essential role in pulpal and periapical diseases [1].

Therefore, the purpose of endodontic treatment is to eliminate microorganisms from the root canal system and to prevent recontamination by creating a seal barrier between the oral microflora and the root canal system and periapical tissue [2]. In reality, creating a fluid-tight apical, lateral and coronal seal is necessary to prevent recontamination and long-term clinical

success [2]. Several root filling materials and techniques have been developed with the purpose of obtaining a tight root canal seal. Ideally, the root canal filling should be a complete, homogeneous mass that fills the prepared canal completely [3]. Mineral trioxide aggregate (MTA) has a variety of potential uses, including a root canal filling material [4-8]. Studies have demonstrated the encouraging regeneration of periradicular tissues, such as periodontal ligament, bone and cementum

when MTA was used in endodontic procedures [4,9].

There are also several reports of its superior biocompatibility with periodontal tissues [10], excellent sealing ability in the presence of moisture [11] and appropriate mechanical properties as apical sealing material [10]. These encouraging outcomes from in vivo and in vitro studies have prompted many clinicians to consider the use of MTA as a root end filling material and as a material suitable for repairing perforations and performing apexification [4,9].

MTA has been used for apexification of immature roots instead of calcium hydroxide [Ca(OH)₂] because it facilitates the normal periradicular architecture by inducing hard tissue barriers [4].

Recently, great interest has been focused on the evolution of Portland Cement (PC) as an alternative to MTA and several studies have compared both materials [12]. PC differs from MTA by the absence of bismuth ions [13] and the presence of potassium ions [14].

Both materials have comparable antibacterial activity [15] and almost identical properties macroscopically, microscopically and by X-ray diffraction analysis [16].

It has also been shown that PC and MTA have similar effects on pulpal cells when used for direct pulp capping in rat teeth [17].

Taking into account the low cost and apparently similar properties of PC in comparison to MTA, it is reasonable to consider PC as a possible substitute for MTA in endodontic applications [14,18].

The purpose of this in vitro study was to evaluate the apical sealability of white-colored MTA (WMTA) and grey-colored PC (GPC) when used alone or as a sealer with gutta-percha points in root canal filling.

MATERIALS AND METHODS

Selection of teeth

Eighty-one recently extracted for several reasons, single-rooted, permanent human teeth were selected.

The teeth with open apical cracks and resorptive defects were excluded and stored in saline solution until they were used. After that, the teeth were cleaned and X-rays were taken to assess the absence of anatomical anomalies in the canal system.

Preparation

After creation of the coronal access, canal length was determined by placing a #10 stainless steel K file (Dentsply Maillefer, Ballaigues, Switzerland) through the canal space until it could be visualized exiting the apical foramen. Working file length was determined by subtracting 1 mm from the length.

The coronal and middle two thirds of these canals were prepared sequentially with size 2, 3, and 4 Gates-Glidden burs (Dentsply Maillefer, Ballaigues, Switzerland) and the apical third of the canals was prepared with hand files (Dentsply Maillefer, Ballaigues, Switzerland) using the step-back technique. Irrigation was carried out using 5.25% sodium hypochlorite solution between the files.

After preparation, the canals were irrigated with 1 ml of 17% EDTA solution (MD-Cleanser, META Biomed, Cheongju, Korea) for 60 seconds to remove the smear layer, because it contains bacteria and may proliferate into the dentinal tubules which may serve as a reservoir of microbial irritants [19].

It may act as a substrate for bacteria, allowing their deeper penetration in the dentinal tubules [19].

The final irrigation was performed with 1 ml of distilled water.

The canals were then dried with sterile paper points (ALPHA-DENT, North Hamlin Avenue, Lincolnwood, USA).

Obturation

The teeth were randomly divided into five equal groups of 15 teeth each, according to the root canal filling material used:

Group1: WMTA alone (ProRoot MTA, Dentsply, Tulsa, USA).

Group2: GPC alone (Syrian company, Tartuos, Syria) was previously sterilized with dry heat cycle 170°C for one hour.

Group3: Gutta-percha points (ALPHA-DENT, North Hamlin Avenue, Lincolnwood, USA) laterally condensed with WMTA (ProRoot MTA, Dentsply, Tulsa, USA).

Group4: Gutta-percha points (ALPHA-DENT, North Hamlin Avenue, Lincolnwood, USA) laterally condensed with GPC (Syrian company, Tartuos, Syria).

Group5: Gutta-percha points (ALPHA-DENT, North Hamlin Avenue, Lincolnwood, USA) laterally condensed with AH26 sealer (Dentsply, Detrey GmbH, Konstanz, Germany) which was considered as the control group because it is a standard material in root canal filling.

To test the nail varnish sealability and the penetrability of the dye in the root canal, three roots were obturated using gutta-percha points (ALPHA-DENT, North Hamlin Avenue, Lincolnwood, USA) laterally condensed with Zinc Oxide-Eugenol sealer (Z.O.E) (S.S.White, Artigos Dentários Ltda, Brasileira) and considered as a positive control group.

In addition, three roots were left empty without obturation and considered as the negative control group.

In the third and fourth groups, gutta-percha points were used to facilitate retreatment.

MTA and AH26 were prepared according to manufacturer recommendations; PC was mixed by adding distilled water to the powder at the same proportion recommended by the manufacturer of MTA.

In the first and second groups, the mixed cements were applied to the canal walls with a lentulo spiral at slow speed and the fresh mix was then incrementally packed in the root ca-

nals using measured finger endodontic pluggers (Dentsply, Maillefer, Swiss). To control placement and manipulation of the MTA and PC, large paper points (ALPHA-DENT, North Hamlin Avenue, Lincolnwood, USA) were used to blot the excess moisture from the cement and to assist in the vertical condensation of MTA and PC.

In the third, fourth and fifth groups, the mixed cements were applied to the canal walls with a lentulo spiral at slow speed and the teeth were filled by the lateral condensation technique.

Excess gutta-percha and cement were removed with a heated plugger and vertically condensed. Each tooth was radiographed to confirm the length and density of the root canal obturation.

After that, glass ionomer cement (GIC) (Restomolar, DenCare, England, UK EEC) was placed in the access opening of all groups and the teeth were stored in 100% humidity at 37°C for 7 days to allow the obturation materials to set.

Next, all groups were removed from the incubator, dried and then the teeth surfaces were coated with two layers of nail varnish leaving the apical foramen of the root exposed.

The negative control group was completely coated with two layers of nail varnish, including the apical foramen.

All specimens were immersed in 2% methylene blue solution (100% humidity at 37°C) for 24 hours.

Subsequently, the teeth were rinsed under running water and allowed to dry.

The teeth were sectioned longitudinally in a buccolingual direction with a diamond straight fissure bur (1.6 mm in diameter and 8 mm in length) using a high speed hand piece with water coolant.

Then, the sections were examined by a stereomicroscope (X 20 magnification) (Meiji techno, Model SKT 41323, Japan) for evaluation of linear dye penetration at the tooth-material interface.

The linear apical leakage was measured from the distance of the anatomical apex to the maximum extent of dye penetration in the coronal direction.

The greatest extent of linear dye penetration was recorded using electronic digital caliper (Lezaco®, China, measuring range 0-150 mm).

Assessment of apical leakage

Escobar et al's [20] criteria was used to evaluate the infiltration proportions:

0-Infiltration loss (dye penetration $0 < 1.5$ mm).

1-Simple infiltration (dye penetration $1.5 - 3$ mm).

2-Medium infiltration (dye penetration > 3 mm).

Data Management

Statistical analysis of the data was accomplished using a Kruskal-wallis test at a significance level of 0.05. We also used statistical tests that depended on the arithmetic means and the standard deviations to obtain more clear and precise results. So, one-way ANOVA analysis was used to compare the linear dye penetration values at a significance level of 0.05 According to the type of the variables and their distribution, we used the parametric one-way ANOVA or non-parametric Kruskal-Wallis test for statistical analysis.

RESULTS

The scores for apical dye penetration evaluation by Escobar et al criteria are shown in Table I. The extent of dye penetration in millimeters, the means and the standard deviations for each group are listed in Table II.

All groups demonstrated dye leakage. Apical dye penetration in the materials of five groups are seen in Figures [I-VI].

The three roots in the positive control group showed dye penetration throughout the entire length of the root canal, whereas all three roots in the negative control group showed no evi-

dence of dye penetration which proves that the conditions of the tests are correct.

Data for apical leakage were subjected to a Kruskal-Wallis test, there were no statistically significant differences among the materials of five groups ($\chi^2 = 4.672$, $df = 4$, $P = 0.323$, P -value > 0.05).

Data were also subjected to one-way ANOVA analysis, there were no statistically significant differences among the materials of five groups ($F = 2.175$, $P = 0.081$, P -value > 0.05).

DISCUSSION

Three-dimensional hermetic sealing of the root canal is one of the main goals of endodontic treatment and is essential for preventing apical and coronal leakage in the root canal system [21]. Inadequate filling may result in fluid movement into the filling defects, inducing a periapical chronic inflammatory reaction and compromising the treatment success [22].

Several test methods have been described to evaluate the sealing quality of obturated root canals [21]. The most popular method is the dye penetration test. Dye penetration studies are commonly used because they are easy to accomplish and do not require sophisticated materials [21].

Methylene blue dye was used in this study because it easily allows quantitative measurement of the extent of dye penetration by linear measurement techniques.

Its molecular size is similar to bacterial by products such as butyric acid which can leak out of infected root canals to irritate periapical tissues [23].

Cleaning the dentinal surface by removing the smear layer is an essential step in the process of successful root canal treatment [19]. In the present study, the smear layer was removed by EDTA in order to improve the adaptation of the cement to the canal wall [3,24,25].

Removing the smear layer does not increase the leakage because most in vitro and in vivo studies that evaluated MTA in root canal

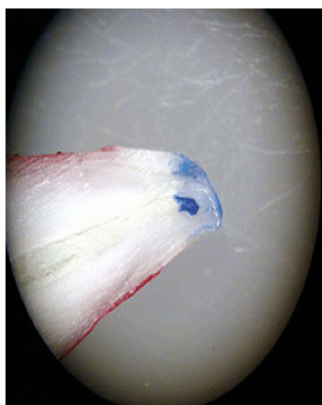


Fig I. Infiltration loss (material: WMTA alone)

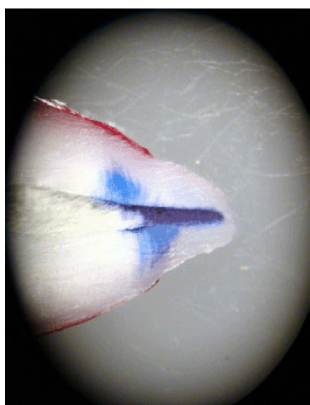


Fig II. Medium infiltration (material: WMTA alone)

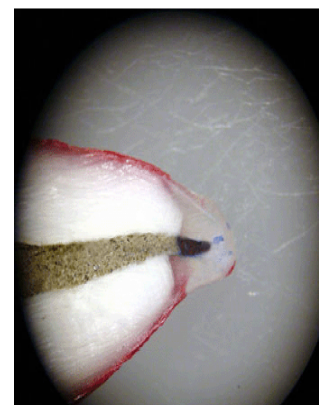


Fig III. Infiltration loss (material: GPC alone)

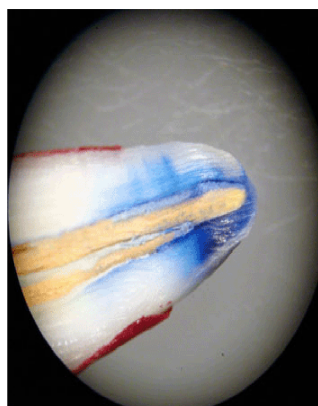


Fig IV. Medium infiltration (material: Gutta-percha points + WMTA)

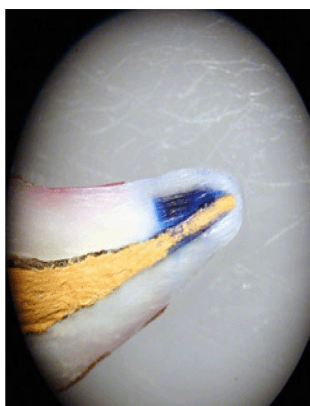


Fig V. Simple infiltration (material: Gutta-percha points + GPC)

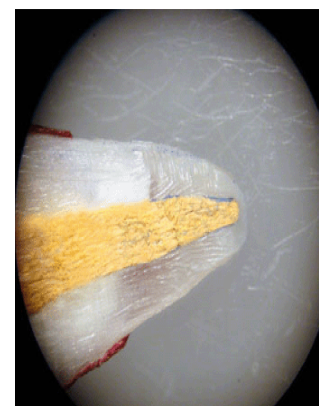


Fig VI. Simple infiltration (material: Gutta-percha points + AH26)

filling have used EDTA for removing the smear layer [3,24,25].

Although removal or retention of the smear layer before canal obturation still remains controversial [26]. If smear layer removal is not implemented, it does not appear to affect the sealability of MTA and its presence might actually improve the seal over time [27].

The apical microleakage of MTA is less when the smear layer is present compared to when it is absent [27].

It has been speculated that the smear layer might act as a (coupling agent) that might enhance MTA bonding to root canal dentin [27]. MTA is a type of hydraulic cement that can set in the presence of water [4]. The smear layer is a more or less moist layer [27]. The moist environment caused by the smear layer might have a positive effect on the adaptation of MTA to the root canal wall [27]. Because the present data are inconclusive regarding smear layer removal, clinicians might choose

Table I. Scores for apical dye penetration evaluation by Escobar et al criteria

Group	Score		
	0	1	2
WMTA alone	4	5	6
GPC alone	5	3	7
Gutta-percha points + WMTA	7	2	6
Gutta-percha points + GPC	4	5	6
Gutta-percha points + AH26	6	9	0

(0. Best; 2. Worst)

to leave the smear layer in selected cases and fill canals with MTA without apparently compromising the outcome [33]. In our study, the controls behaved as expected which confirms the methodology used. The results of this study showed that the materials of five groups presented similar apical sealability. Several studies have reported excellent results when using MTA in endodontic treatment [4]. The factor responsible for the beneficial effects in MTA is also found in PC [28]. This has resulted in a significant body of research [6,15] that shows PC appears to be a useful substitute for MTA [17].

Danesh et al [29] showed that MTA displayed superior material properties compared to PC, which was significantly more soluble, reached lower microhardness values and was less radiopaque. The lack of radiopacity in pure PC is

due to the absence of bismuth, a chemically inert radiopacifier in its composition [13]. However, our results differ from those of Vizgirda et al [30], who reported that the apical seal produced by laterally condensed gutta-percha with Roth's 801 sealer was superior to that produced by gutta-percha with MTA. The difference in results could be attributed to the following reasons: (a) In our study, dye penetration was evaluated by buccolingual longitudinal sections method as opposed to the teeth clearing technique; (b) human teeth were used here instead of bovine teeth; (c) besides; the difference could be attributed to the type of sealer used; (d) canal preparation was accomplished by using the crown-down technique as opposed to step-back canal preparation with LightSpeed instruments and saline; (e) the apical portion of the root canal was prepared to

Table II. Extent of apical dye penetration (mm)

Group	n	Minimum	Maximum
Mean	SD		
WMTA alone	15	0.29	5.55 2.47 1.53
GPC alone	15	0.25	5.88 3.01 1.82
Gutta-percha points + WMTA	15	0.16	4.45 2.20 1.51
Gutta-percha points + GPC	15	0.12	5.78 2.72 1.85
Gutta-percha points + AH26	15	0	2.85 1.46 0.91

n = Number, SD = Standard Deviation

2010; Vol. 7, No. 4

a #80 with Light Speed nickel-titanium rotary instruments; (f) without removing the smear layer.

The findings of the present study are in contrast with those obtained by Tabrizizadeh et al [31].

They assessed the apical sealability of MTA alone and laterally condensed gutta-percha with AH26, and showed that the canal obturation with gutta-percha and AH26 sealer may provide a better apical seal compared with MTA alone.

The difference could be attributed to the method of dye penetration evaluation (teeth clearing), besides the smear layer was not removed.

Al-Hezaimi et al [32] used human saliva penetration and showed that MTA alone is better than vertically condensed gutta-percha and Kerr Pulp Canal Sealer EWT (Zinc oxide-eugenol based sealer). The difference could be attributed to the leakage measured by bacterial penetration as opposed to dye penetration, the type of sealer used and the condensation technique.

Clinical support for the use of MTA as an obturating material, however, was presented in some case reports. In a case report, O'Sullivan and Hartwell [33] used MTA alone as the obturating material for the root canal system of a retained primary second molar. At the 4-month follow-up, the patient was asymptomatic, clinical findings were within normal limits and there was evidence of radiographic healing. In another case report, MTA separately was used for obturation of the root canal system of two mature mandibular central incisors with apical periodontitis. A 2-year follow-up radiographic examination demonstrated the dramatic regeneration of the periradicular tissue [24].

Extrapolation of the results of this in vitro study into clinical reality must be performed with caution. Post space preparation is often required immediately following root canal obturation with MTA or PC each separately. In

addition, retrieving the set MTA or PC alone from the root canal is difficult if nonsurgical retreatment is indicated.

Therefore, it is recommended that root canal filling with MTA or PC separately should be limited to selected cases such as one-visit apexification and situations where future nonsurgical retreatment is nonfeasible or may not render better tooth prognosis.

Further investigation should be conducted to determine whether some physical properties of MTA and PC or the technique for its placement could be modified to facilitate its use as a root canal filling material.

CONCLUSION

Within the limitations of this study, both WMTA and GPC alone produced the apical sealability equal to that produced by gutta-percha points and lateral condensation techniques.

ACKNOWLEDGMENTS

I would like to express my deep appreciation to Professor Mohammad Salem Rekab, Department of Endodontics, Faculty of Dentistry, Damascus University for the time and effort he has spent on reviewing this article and giving valuable comments.

REFERENCES

- 1-Sunqvist G. Ecology of the root canal flora. *J Endod* 1992 Sep;18(9):427-30.
- 2-Siqueira Jr JF. Strategies to treat infected root canals. *J Calif Dent Assoc* 2001 Dec;29(12):825-37.
- 3-Mohammadi Z. Sealing Ability of MTA Cements as Orthograde Root Filling Materials. *Pesq Bras Odontoped Clin Integr* 2008 Sep;8(3):267-70.
- 4-Torabinejad M, Chivian N. Clinical applications of mineral trioxide aggregate. *J Endod* 1999 Mar;25(3):197-205.
- 5-Holland R, de Souza V, Nery MJ, OtoboniFilho JA, Bernabé PF, Dezan Júnior E. Reaction of dogs' teeth to root canal filling with mineral trioxide ag-

- gregate or a glass ionomer sealer. *J Endod* 1999 Nov;25(11):728-30.
- 6-Holland R, Souza V, Nery MJ, Bernabé PFE, OtoboniFilho JA, Dezan Júnior E. Agregado de trióxido mineral y cemento Portland en la obturación de conductos radiculares de perro. *Endodoncia* 2001 Oct./Dec;19(4):275-80.
- 7-Johnson JD. Root canal filling materials. In: Ingle JI, Bakland LK, Baumgartner JC, eds. *Ingle's Endodontics* 6. 6th ed. Hamilton: BC Decker Inc; 2008. p. 1030-1.
- 8-Glickman GN, Walton RE. Obturation. In: Walton RE, Torabinejad M, eds. *Endodontics principles and practice*. 4th ed. St Louis: Saunders Elsevier Inc; 2009. p. 318.
- 9-Giuliani V, Baccetti T, Pace R, Pagavino G. The use of MTA in teeth with necrotic pulps and open apices. *Dent Traumatol* 2002 Aug;18(4):217-21.
- 10-Torabinejad M, Pitt Ford TR, McKendry DJ, Abedi HR, Miller DA, Kariyawasam SP. Histologic assessment of mineral trioxide aggregate as a root-end filling in monkeys. *J Endod* 1997 Apr;23(4):225-8.
- 11-Torabinejad M, Higa RK, McKendry DJ, Pitt Ford TR. Dye leakage of four root end filling materials: effects of blood contamination. *J Endod* 1994 Apr;20(4):159-63.
- 12-Bortoluzzi EA, Broon NJ, Bramante CM, Garcia RB, de Moraes IG, Bernardineli N. Sealing ability of MTA and radiopaque Portland cement with or without calcium chloride for root-end filling. *J Endod* 2006 Sep;32(9):897-900.
- 13-Coomaraswamy KS, Lumley PJ, Hofmann MP. Effect of bismuth oxide radiopacifier content on the material properties of an endodontic Portland cement-based (MTA-like) system. *J Endod* 2007 Mar;33(3):295-8.
- 14-Saidon J, He J, Zhu Q, Safavi K, Spangberg LS. Cell and tissue reactions to mineral trioxide aggregate and Portland cement. *Oral Surg Oral Med Oral Pathol Oral Radiol Endod* 2003 Apr;95(4):483-9.
- 15-Estrela C, Bammann LL, Estrela CR, Silva RS, Pécora JD. Antimicrobial and chemical study of MTA, Portland cement, calcium hydroxide paste, Sealapex and Dycal. *Braz Dent J* 2000 Jan;11(1):3-9.
- 16-Song JS, Mante FK, Romanow WJ, Kim S. Chemical analysis of powder and set forms of Portland cement, gray ProRoot MTA, white ProRoot MTA, and gray MTA-Angelus. *Oral Surg Oral Med Oral Pathol Oral Radiol Endod* 2006 Dec;102(6):809-15.
- 17-Wucherpfenning AL, Green DB. Mineral trioxide vs Portland cement: two biocompatible filling materials. *J Endod* 1999 Feb;25(4):308.
- 18-De Deus G, Ximenes R, Gurgel-Filho ED, Plotkowski MC, Coutinho-Filho T. Cytotoxicity of MTA and Portland cement on human ECV 304 endothelial cells. *Int Endod J* 2005 Sep;38(9):604-9.
- 19-Zmener O, Pameijer CH, Banegas G. Effectiveness in cleaning oval-shaped root canals using Anatomic Endodontic Technology, ProFile and manual instrumentation: a scanning electron microscopic study. *Int Endod J* 2005 Jun;38(6):356-63.
- 20-Escobar C, Michanowicz AE, Czonstkowsky M, Miklos FL. A comparative study between injectable low-temperature (70 degrees C) gutta-percha and silver amalgam as a retroseal. *Oral Surg Oral Med Oral Pathol Oral Radiol Endod* 1986 May;61(5):504-7.
- 21-Bodrumlu E, Tunga U. Apical leakage of Resilon obturation material. *J Contemp Dent Pract* 2006 Sep 1;7(4):45-52.
- 22-Valera MC, Camargo CH, Carvalho AS, Gama ER. In vitro evaluation of apical microleakage using different root-end filling materials. *J Appl Oral Sci* 2006 Jan;14(1):49-52.
- 23-Kersten HW, Moorer WR. Particles and molecules in endodontic leakage. *Int Endod J* 1989 May;22(3):118-24.
- 24-Hayashi M, Shimizu A, Ebisu S. MTA for obturation of mandibular central incisors with open apices: case report. *J Endod* 2004 Feb;30(2):120-2.
- 25-Mohammadi Z, Yazdizadeh M, Khademi A. Sealing ability of MTA and a new root filling material. *Clin Pesq Odontol Curitiba* 2006 Dec;2(5):367-71.

- 26-Torabinejad M, Handysides R, Khademi AA, Bakland LK. Clinical implications of the smear layer in endodontics: a review. *Oral Surg Oral Med Oral Pathol Oral Radiol Endod* 2002 Dec;94(6):658-66.
- 27-Yildirim T, Oruçoğlu H, Çobankara FK. Long-term evaluation of the influence of smear layer on the apical sealing ability of MTA. *J Endod* 2008 Dec;34(12):1537-40.
- 28-Spangberg LS. Response to letter to the editor by Carolyn M. Prismus, PhD. *Oral Surg Oral Med Oral Pathol* 2006 Apr;101(4):418.
- 29-Danesh G, Dammaschke T, Gerth HUV, Zndbiglari T, Schafer E. A comparative study of selected properties of ProRoot mineral trioxide aggregate and two Portland cements. *IntEndod J* 2006 Mar;39(3):213-9.
- 30-Vizgirda PJ, Liewehr FR, Patton WR, McPherson JC, Buxton TB. A comparison of laterally condensed gutta-percha, thermoplasticized gutta-percha, and mineral trioxide aggregate as root canal filling materials. *J Endod* 2004 Feb;30(2):103-6.
- 31-Tabrizizadeh M, Mohammadi Z, BarzegarBarfruyi MJ. Comparison of the apical leakage of root canals filled with MTA with those filled guttapercha and lateral condensation technique. *J Dental Med* 2008 July;20(4):263-7.
- 32-Al-Hezaimi K, Naghshbandi J, Oglesby S, Simon JH, Rotstein I. Human saliva penetration of root canals obturated with two types of mineral trioxide aggregate cements. *J Endod* 2005 Jun;31(6):453-6.
- 33-O'Sullivan SM, Hartwell GR. Obturation of a retained primary mandibular second molar using mineral trioxide aggregate: a case report. *J Endod* 2001 Nov;27(11):703-5.